



Hematology Analysis Report

Patient: MILKY Species: Feline Patient ID: 260331004
 Client: NERCUIT Gender: Female Sample No.: 08
 Doctor: DR. LOVELY TAN Age: 3Months Time of analysis: 2026/04/07 13:15

Para.	Current result	Ref. Ranges	2026/03/31
WBC	H 28.98 10 ⁹ /L	5.50-19.50	33.63
Neu#	H 18.11 10 ⁹ /L	1.80-12.60	23.01
Lym#	5.19 10 ⁹ /L	0.80-7.90	4.00
Mon#	1.77 10 ⁹ /L	0.00-1.80	1.95
Eos#	H 3.91 10 ⁹ /L	0.00-1.90	4.67
Neu%	0.625	0.300-0.850	0.684
Lym%	0.179	0.100-0.530	0.119
Mon%	0.061	0.000-0.100	0.058
Eos%	H 0.135	0.000-0.110	0.139
RBC	6.30 10 ¹² /L	5.10-11.20	6.55
HGB	112 g/L	85-162	118
HCT	0.295	0.260-0.510	0.324
MCV	46.8 fL	35.0-54.0	49.4
MCH	17.7 pg	11.8-18.0	18.0
MCHC	378 g/L	300-380	364
RDW-CV	0.187	0.132-0.256	0.196
RDW-SD	36.1 fL	23.7-45.6	39.8
PLT	H 783 10 ⁹ /L	100-518	653
MPV	12.1 fL	8.2-16.3	11.7
PDW	14.6	12.0-17.5	15.1
PCT	H 9.45 mL/L	0.90-7.00	7.63

Operator:

The results only applies to this test sample.

Test Instrument: Mindray BC-30 Vet

Time of Printing: 2026-04-07 13:30:09



PETVET CENTRAL VET CLINIC – BARRA
 ZONE 4, BARRA, OPOL, MISAMIS ORIENTAL
 0927 569 8880

Global Pioneer of Comprehensive Animal Medical Solutions
 Better healthcare for all - Since 1991

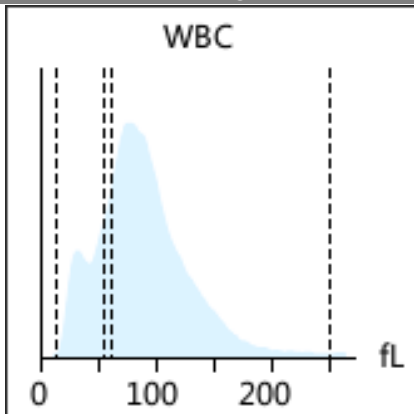
mindray
 animal medical



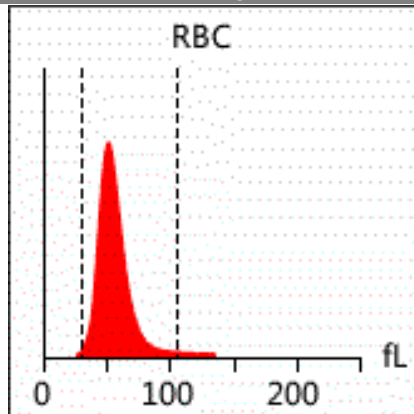
Hematology Analysis Report

Patient:	MILKY	Species:	Feline	Patient ID:	260331004
Client:	NERCUIT	Gender:	Female	Sample No.:	08
Doctor:	DR. LOVELY TAN	Age:	3Months	Time of analysis:	2026/04/07 13:15

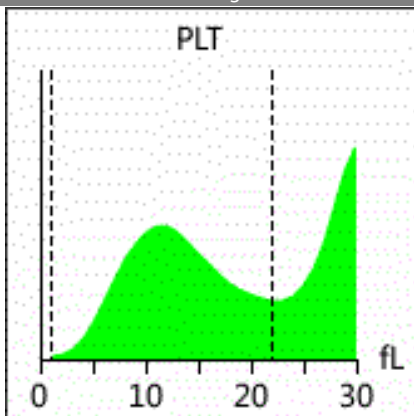
WBC Histogram



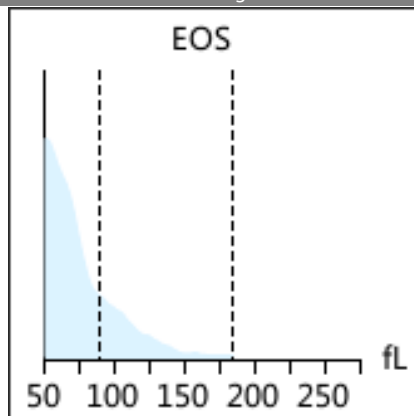
RBC Histogram



PLT Histogram



EOS Histogram



Diagnosis implications:

Leucocytosis
Thrombocytosis

Neutrophilia

Eosinophilia

Report Explan.

Leucocytosis	It occurs in bacterial infection, burn, post-operation, malignant tumor, leukemia, etc
Neutrophilia	It occurs in stress response or corticosteroid response, inflammation, granulocytic leukemia
Eosinophilia	It occurs in allergy, parasite infection, eosinophilic granuloma, feline bronchial asthma, eosinophilic gastroenteritis/colitis, infectious diseases, and tumors (such as mast cell tumor)
Thrombocytosis	It occurs in reactive thrombocytosis, such as chronic inflammation, immune-mediated anemia, drug treatment, and iron deficiency anemia, or it occurs in neoplastic thrombocytosis

Note: Due to the complexity and individuality of disease diagnosis, the report interpretation is only for your reference. Please consult your doctors for clinical diagnosis results. The results only applies to this test sample.

Test Instrument: Mindray BC-30 Vet Time of Printing: 2026-04-07 13:30:09



PETVET CENTRAL VET CLINIC – BARRA
ZONE 4, BARRA, OPOL, MISAMIS ORIENTAL
0927 569 8880

Global Pioneer of Comprehensive Animal Medical Solutions
Better healthcare for all - Since 1991

mindray
animal medical